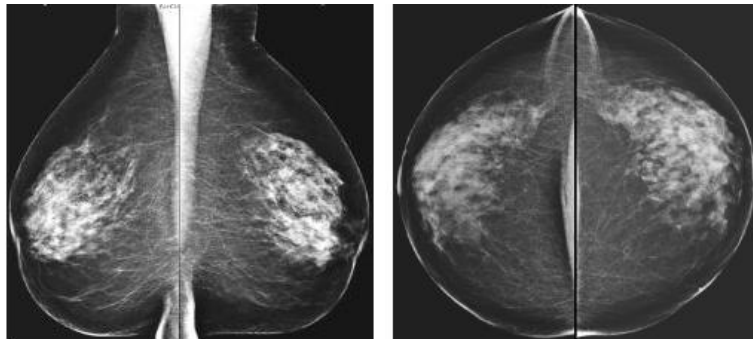


# DMXI

## Diagnostic Medical X-Ray and Imaging

### State of the Art Outpatient Imaging Center

#### EDUCATE YOURSELF ON THE BASICS OF BREAST CANCER AND BREAST IMAGING



Your Doctor *already knows*

*Image is everything at DMXI*

Convenient location  
Convenient scheduling

---

Every aspect of health care is learning new things every day, but is extraordinarily true for the field of radiology. It takes time to bring new types of imaging from the research level to the neighborhood near you.

It takes time to learn about the different ways diseases can be detected and ways diseases can be missed. *It is most important to remember that the vast majority of breast cancer has already been present 15 – 20 years in your breast before it is detected at a small size of less than 1 centimeter.* Science is still learning what happens to the cancer cells to make them more dangerous, grow bigger and spread faster, whereas some cancers may not hardly change at all. There are several kinds of breast cancer and each of them behaves differently. This presents a great challenge to the art of medicine. There are several ways to image the breast. These include:

Mammography                      Ultrasound  
Breast MRI                          Nuclear Imaging

Each test has strengths and weaknesses. Please read on for a brief example of each type. Your doctor will advise you on which is most appropriate for you given each person's individual circumstances.

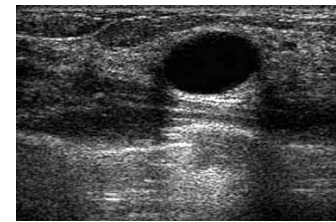
---

**MAMMOGRAPHY:** This is the most cost effective screening procedure currently available. It can detect some cancers depending on size and it can miss cancers, especially when small. It is the only test to detect tiny calcifications, which can be an early sign of breast cancer. It is very good in patients whose breasts have more fat in them or have mild to moderately dense glandular tissue. HOWEVER, it has significant limitations in women whose breasts are moderate to severely dense with glandular tissue. A young woman in her teens or twenties

has dense breast tissue, which is sensitive to radiation. An alternate test such as ultrasound should be done first, with possible mammography or breast MRI. Mammography may still need to be done.

---

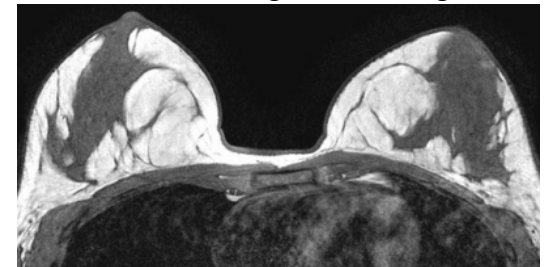
**Breast Ultrasound:** This is a very good test for problem solving. The density of glandular tissue does not limit this test. This is commonly used for determining if a lump is real, a cyst or a solid tumor. A vast majority of aspirations



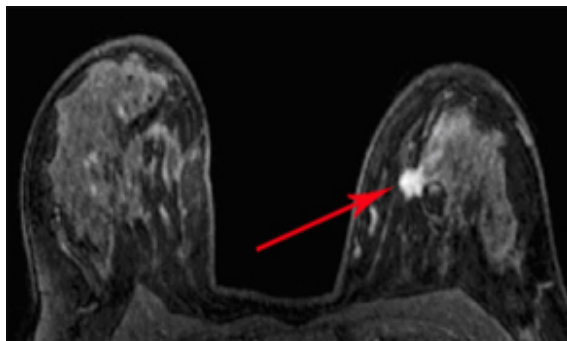
and biopsies are performed under ultrasound guidance because the doctor should be able to see the needle entering the cyst or tumor. However, sometimes benign looking findings can turn out malignant and sometimes even suspicious ultrasound findings thankfully turn out benign. (Image is a simple cyst)

---

**Breast Magnetic Resonance Imaging:** Breast MRI has been performed in Europe for more than 15-20 years and in the United States for at least the last 4 years and under research for another 4 years prior. Breast MRI is unaffected by the density of glandular tissue of the breast and is not dependent on radiation. This makes it an ideal test for those women who have increased dense glandular tissue, which would limit the mammogram. It has great value in the evaluation of young women and would be especially important in the woman who has a strong family history for breast cancer. Breast MRI could be used in the



evaluation of a lump or site of pain in which mammography, ultrasound, or even biopsies have been shown to be negative for cancer. Breast MRI can be utilized in the evaluation of breast implants for the detection of rupture. Breast MRI is also utilized to detect additional sites of breast cancer in women already diagnosed with breast cancer, whether it is found in the affected breast or opposite breast. A limitation of Breast MRI is that it cannot detect tiny calcifications; very small or non-vascular malignant tumors can be difficult to find or can appear benign. Sometimes there is motion artifact from the adjacent heart and from breathing. (2 Images of Breast MRI )



of Breast MRI is that it cannot detect tiny calcifications; very small or non-vascular malignant tumors can be difficult to find or can appear benign. Sometimes there is motion artifact from the adjacent heart and from breathing. (2 Images of Breast MRI )

### How is a Breast MRI performed?

After changing into a gown, you will be brought into the MRI room. The technologist will explain the test. You will need to lie face down and the technologist assists you for positioning in the MRI unit. It is very important that you hold still through the exam for best imaging quality and clarity. Breast MRI involves the use of contrast that is injected into your vein. The exam takes approximately 35 minutes.

**Nuclear Imaging:** Is sometimes used as problem-solving test for the breast. It helps detect benign or malignant tumors, but it cannot help determine which is which. The glandular density of the breast does not affect it. But it is not helpful for specific biopsy guidance. It is as expensive as Breast MRI.

### What to do next?

1. Begin or continue monthly self-breast examination.
2. Ask your doctors which test is appropriate for you.
3. Ask if your mammogram was compared to enough previous mammograms to prove if another test is necessary. The mammogram might need to be looked at again, comparing it to exams 3-6 years before your current mammogram. This helps eliminate the need for unnecessary tests.
4. Talk to your doctor about Breast MRI.

### MAMMOGRAPHY AT DMXI

DMXI offers both screening and diagnostic mammography services on a timely fashion, and walk-ins are welcome. We will obtain old mammography studies to compare with. You may bring old exams with you or we will send for them. It is best for you to get as many old mammograms as possible for comparison. For your convenience and comfort we offer a private waiting area and dressing rooms. A certified technologist performs your test. Your films are developed while you wait to insure quality of your images. A Board Certified radiologist is present to review your films and is available to answer your questions, or you can schedule an appointment to go over your films and results.

Types of mammograms:

**Screening** - yearly exam with no problems and no prescription is necessary.

**Diagnostic** - requires a script from physician -patient has specific complaint, lump, pain etc

If a biopsy is needed, DMXI uses vacuum assistance to obtain a better specimen. This biopsy device can be used for both ultrasound and MRI.

Second to monthly self-breast exams and a yearly physical exam by your physician, imaging of the breast is extremely helpful.

## Breast Imaging Services at DMXI

**Screening & Diagnostic Mammography**  
**Breast Ultrasound**  
**Ultrasound Directed Biopsies**

*These tests can be scheduled promptly and biopsy results are typically provided the next day.*

**Additional services include: CAT Scans, MRI, General X-Ray and DEXA scans**

*“At DMXI you’ll feel good about the way we see you.”*

8390 Tod Ave.  
Boardman, OH 44512

Phone~330-726-6010  
Fax~330-726-6017

